

What I tell my patients about microscopic haematuria ('dipstick haematuria')

Haematuria is the presence of red blood cells in the urine. Large numbers of red blood cells turn the urine red: this is called macroscopic haematuria. On the other hand, microscopic haematuria is the term that doctors use when there are small numbers of red blood cells in the urine.

Asymptomatic microscopic haematuria (AMH) is the term used when a patient has microscopic haematuria but has no symptoms of the disease, and so was unaware that there was anything wrong with them until they had a urine test.

Sometimes the urine test also shows the presence of protein in the urine; this is called proteinuria. The combination of haematuria and proteinuria is more worrying than the presence of haematuria alone. This article concentrates on those people who have AMH without proteinuria.

How common is AMH?

AMH is very common – occurring in up to 3% of healthy men and 8% of healthy women. Most patients with AMH are not destined to develop any serious disease.

The difficulty for doctors seeing patients with haematuria is that, although it is so common, in a small number of people it can be the first sign of serious disease.

What are the causes of AMH?

The causes of AMH include:

- Cystitis – and other infections of the urinary tract – is probably the most common cause of haematuria, although it usually causes symptoms
- Kidney or bladder stones – although these usually cause symptoms in the form of severe pain (renal colic) as the stones pass through the urinary tract and get stuck in the ureters (the tubes that carry urine from each kidney to the bladder) on the way
- Glomerulonephritis – inflammation within the glomeruli (the filters in the kidneys that filter blood to produce a solution which, after further treatment in the kidney tubules,

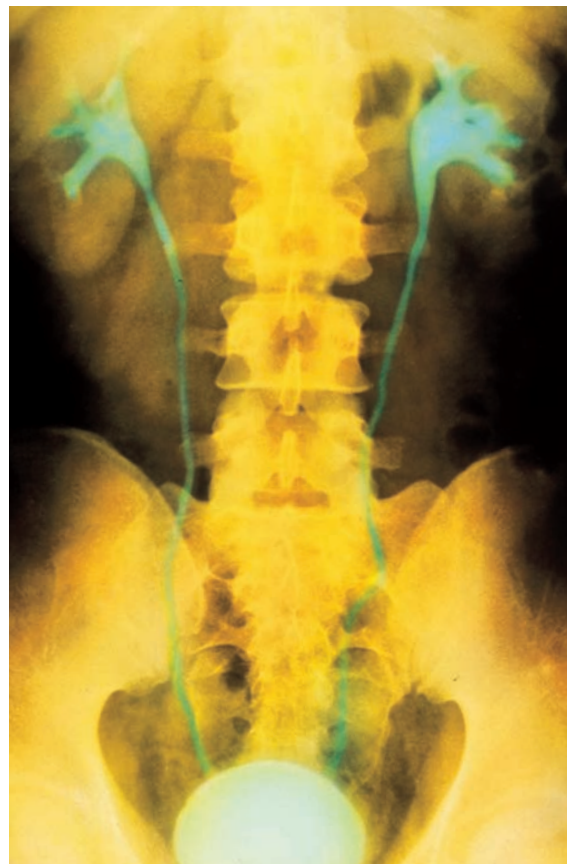becomes urine). There are various types of glomerulonephritis. Most of these result from disorders of the body's immune system, which causes antibodies (which normally help to protect the body against infections) to get stuck in these filters, resulting in inflammation.

This may progress to cause more severe abnormalities, such as proteinuria, high blood pressure, and eventually, impairment of the function of the filters, which if unchecked may result in kidney failure

- Cancer – either of the kidney tissue (renal cell carcinoma) itself, of the lining of the urinary tract (transitional cell carcinoma), or of the prostate gland. Although it is certainly true that these cancers can cause haematuria, they are found in only a small minority of people

Charlie Tomson

BM BCh DM FRCP
Consultant Renal
Physician, The
Richard Bright
Renal Unit
Southmead
Hospital, Bristol



The cause of AMH can be investigated by the use of a number of techniques, including the use of special X-rays called urographies which allow the kidneys and bladder to be seen (as shown in green)



with AMH. In fact, it has been suggested that cancer is no more likely to be found in a patient with microscopic haematuria than in one without

- Inherited diseases of the glomeruli that are sometimes associated with deafness (including Alport's syndrome)
- Thin basement membrane nephropathy – an inherited abnormality which causes the lining of the glomeruli to be unusually thin. This seldom results in progressive kidney damage. There is often a history of haematuria, but not of more serious renal disease, in other family members
- Polycystic kidney disease – an inherited disease causing multiple cysts to develop within both kidneys, often associated with high blood pressure and then progressive kidney failure
- Exercise – even non-contact sports can cause an increase in red cells in the urine in otherwise healthy people. This means that if

Even non-contact sports can cause an increase in red cells in the urine

haematuria is found in a person who regularly takes strenuous exercise it is worth checking again for haematuria after 24 hours without such exercise. The blood cells in the urine in

exercise-induced haematuria probably come from the kidneys, although running can sometimes cause bleeding from the bladder as a result of trauma to the lining of the bladder

- Minor abnormalities – such as benign renal cysts, benign enlargement of the prostate gland, and narrowing of the urethra (the tube which takes urine from the bladder to the

outside). While these are often listed as causes of haematuria, it is often difficult to be sure that these abnormalities are actually the source of the haematuria

- Sickle cell anaemia, and sometimes sickle cell trait.

When is AMH usually detected?

By definition, AMH is detected during routine urine testing or microscopy in patients who have no symptoms to suggest that they have disease of the kidney or bladder. Testing for haematuria may be done during:

- A new patient check, when you first register at a health centre
- A pre-employment medical examination
- A medical examination carried out because you have applied for life insurance
- Health screening at work
- Admission to hospital with an unrelated condition.

The methods of detection

Microscopic haematuria can either be detected using a microscope or by using test strips called dipsticks. The test strip is dipped into the urine sample, any extra urine is shaken off, and then held horizontally for 60 seconds before looking for colour change on the pads.

In the dipstick, shown in the picture opposite, the pad which detects blood is on the bottom of the strip and has green spots on it, indicating the presence of haematuria. The amount of haematuria is reported as trace, 1+, 2+, or 3+. In this instance the patient also has glucose in the urine, showing as a dark green reaction on the middle test pad.

In general, dipstick testing is more reliable than routine microscopy, because red cells may be difficult to recognise under the microscope, and often burst apart during storage of the urine sample. Also, the volume of urine examined in routine lab microscopy is variable.

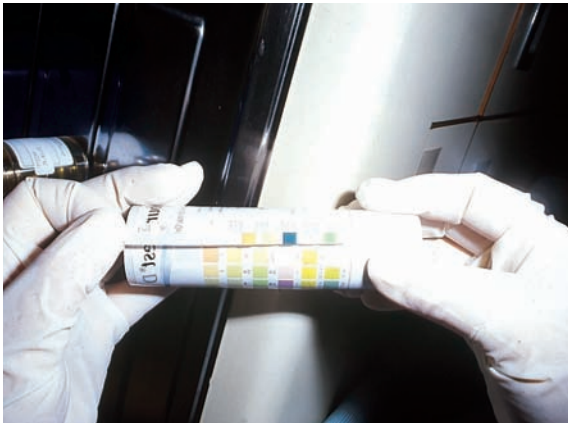
False-positive dipsticks due to chemical contamination of the urine are rare. When patients with dipstick haematuria are investigated for renal disease or urological disease, similar rates of disease are found in those in whom the lab microscopy confirms haematuria and in those with no red cells seen on microscopy.

These findings mean that it is wiser to rely on the dipstick test than routine lab microscopy. However, careful microscopy of the urine may be helpful not only in detecting red cells in the urine, but also in helping to detect other abnormal cells, for instance cancerous cells.

Automated analysis of the size of urinary red cells may also suggest where they came from (because red cells which have passed through the



Use of an inverted microscope in the routine microbiology lab to examine urine samples



Dipsticks can be used to test for AMH. This dipstick result shows green spots on the bottom of the strip indicating the presence of haematuria

renal tubules tend to become shrunken and distorted) and, for example, distinguish bleeding from the glomeruli within the kidney from bleeding from the lining of the urinary tract.

The frequency and severity of AMH

Sometimes, AMH can be intermittent, but just because it may come and go, does not mean that it can be ignored. Both in patients with transitional cell cancers and in patients with proven glomerulonephritis, intermittent haematuria is well described. However, it is probably reasonable to ignore a single finding of haematuria if repeated subsequent tests for it are negative.

It is unlikely that there is any relationship between the severity of haematuria and the likelihood of finding an important abnormality or investigation. The amount of blood in the urine does not seem to be an important indicator of whether there is a serious cause. All agree that it is important to rule out cancer, even in patients with very small degrees of haematuria.

Identifying the cause of AMH

If enough tests are done, a cause for haematuria can nearly always be found. The difficulty is in deciding how many tests an individual patient should have.

In menstruating women, it is obviously important to be sure that the urine is not contaminated by menstrual blood, by checking for haematuria between menstrual periods.

Ruling out cancer

Most doctors think that it is important to carry out tests to check for cancer of the kidneys or lining of the urinary tract in patients over 40 years old, and some would recommend such tests in men over 30 years old. So few patients with AMH turn out to have cancer that one might question whether this is sensible.

However, once someone has been told that they have haematuria and that this could be caused by cancer, doing the tests may be the best way of stopping the person worrying. Cancer of the kidneys is detected using either one of the following:

- Intravenous urography – a series of X-rays of the kidneys and bladder involving injection of contrast material (a chemical which shows up on X-rays) which is taken up by the kidneys and passes into the urine
- Renal ultrasound – an examination of the kidneys and bladder using sound waves.

Cancer of the lining of the urinary tract usually starts in the bladder. The early stages cannot be seen on X-ray or ultrasound tests, and are best seen by cystoscopy. This is an examination of the bladder using a flexible fibre-optic instrument that is introduced through the urethra (the tube through which urine is normally passed) under local anaesthetic.

Other more likely causes

These tests will also detect some of the other causes of haematuria, including kidney stones and polycystic kidneys. Isolated cases have been reported in which cancer has developed in patients whose cystoscopy and renal imaging were thought to be normal up to three years earlier, but these cases are so rare that most experts do not recommend repeating the tests.

If renal imaging and cystoscopy show no abnormality, the likely explanation for haematuria is glomerulonephritis. This can only reliably be diagnosed by renal biopsy, where a hollow needle is introduced under local anaesthetic through the skin and muscles of the back, and directed using ultrasound scanning onto the surface of the kidney. It is then inserted into the kidney, trapping a core of kidney tissue within the needle. This core is sent for microscopic examination in the pathology laboratory. Renal biopsy carries a small risk of complications – most importantly, bleeding from the kidneys or surrounding structures.

Once cancer and stone disease have been ruled out, most patients will turn out to have mild glomerulonephritis, and only a small minority of them will develop any evidence of progressive kidney disease. It is impossible to predict (even with renal biopsy) which patients will form this minority. The early signs of progressive kidney damage are:

- High blood pressure (although this can be present for other reasons)
- Proteinuria (protein in the urine)

If enough tests are done, a cause for haematuria can nearly always be found



- A rise in serum creatinine, even within the normal range (serum creatinine is a blood test used to assess kidney function).

It is thought that people with haematuria are only just over twice as likely to develop end-stage kidney failure as people without haematuria over a ten-year period – which is not much of a risk when one considers how rare kidney failure is. However, 5–10% of such patients develop proteinuria within three to four years of observation. This suggests that extended follow-up over more than ten years – maybe as long as

30 years – is important to reveal the risk of kidney failure in the long term.

Without a renal biopsy, one can never be sure why blood is present in the urine

A few patients with otherwise unexplained microscopic haematuria may be passing tiny kidney stones that are too

small to cause any other symptoms or signs. In children, drugs to treat abnormalities in the chemical balance of the urine which lead to stone formation can result in the disappearance of haematuria. Adults with persistent haematuria and normal renal biopsies are more likely to go on to form stones in the future, suggesting that recurrent passage of crystals in the urine may cause haematuria in adults as well as in children. However, most kidney specialists do not routinely test for abnormalities in urine chemistry that might cause stones in adults.

When is a renal biopsy justified in AMH?

Renal biopsy is the only way of finding out whether the glomeruli are abnormal. Without carrying one out, one can never be absolutely sure what the cause of the blood in the urine is. However, the procedure carries risks. A biopsy may be worth performing if:

- Uncertainty over the precise cause of haematuria is causing intolerable anxiety – particularly if there are fears that it is caused by cancer – in which case, proving an alternative diagnosis may be necessary to relieve this anxiety
- Employment prospects depend on the result, for instance recruitment to the army, but not if employment is going to be refused whatever the biopsy shows. This question may need to be settled with the recruiting officer before deciding on a biopsy
- Life insurance is being refused or only offered at a high premium because of the haematuria. In these circumstances, a biopsy showing a very good prognosis may improve the ‘insurability’ of the patient
- There is a family history of kidney disease. In this situation it may be preferable, and safer, to biopsy the parent rather than the child, but only if the paediatric nephrologists believe that

the information will sufficiently alter their management to justify the risk to the parent. Carrying out a biopsy just to find out what’s going on is not a sufficient reason!

What follow-up should be arranged once the cause of AMH has been determined?

If a renal biopsy has been performed and is completely normal further checks should not be necessary. In patients whose biopsy shows glomerulonephritis, and in those who did not have a renal biopsy, an annual check-up will probably be recommended. This should include:

- A dipstick test of the urine to look for proteinuria
- A careful blood pressure measurement
- A blood test (serum creatinine) to look for signs of deteriorating kidney function.

If any of these signs develop, patients could be referred back to the renal clinic, and may need to have a renal biopsy.

Some renal specialists may keep information on a computer database and ask GPs to send in follow-up data once a year, enabling reminder letters to be sent to GPs and/or patients if the data are not received. Such systems fail if patients change their address or GP, so it is up to patients to ensure that these tests are done, and to continue to do so for life, or at least until there is a better way of predicting which patients are destined to develop kidney disease ■

Key points

- **Asymptomatic microscopic haematuria (AMH) is the term used when a patient has microscopic haematuria but has no symptoms of the disease, and so was unaware that there was anything wrong with them until they had a urine test.**
- **AMH is very common – occurring in up to 3% of healthy men and 8% of healthy women. Most patients with AMH are not destined to develop any serious disease.**
- **Microscopic haematuria can either be detected using a microscope or by using test strips called dipsticks.**
- **Once cancer and stone disease have been ruled out, most patients will turn out to have mild glomerulonephritis, and only a small minority of them will develop progressive kidney disease.**